Caso Clínico

Cisto residual apical | Mandibula / Enxerto beta trifosfato de calcio

Depto. Clínico Bionnovation – Dr. Carlos A. A. Oliveira

Apresentação do Procedimento

Paciente sexo masculino, 66 anos,branco,apresentando lesão radiolúcida de aspecto cístico, evolução de 5 anos,indolor, abaulamento dos dentes envolvidos e creptação óssea da parede vestibular

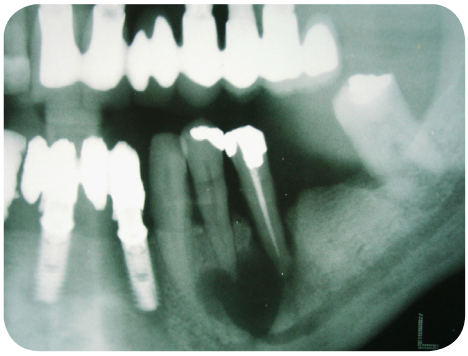

Lesão radiolúcida envolvendo dentes 33, 34 e 35

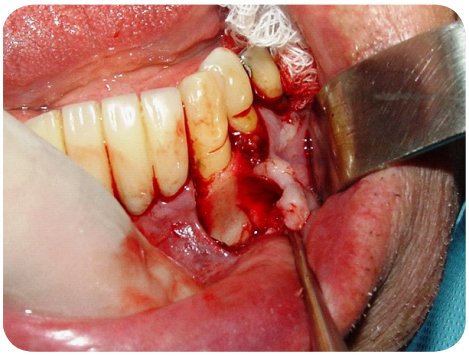

Descolamento do retalho cirúrgico

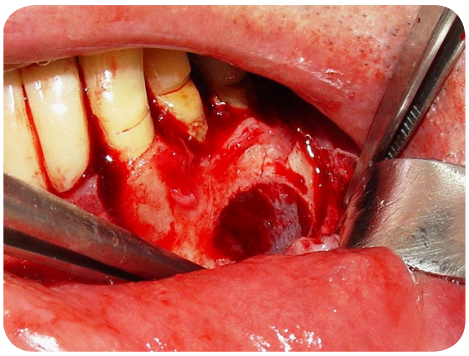

Descolamento do periósteo junto com o retalho

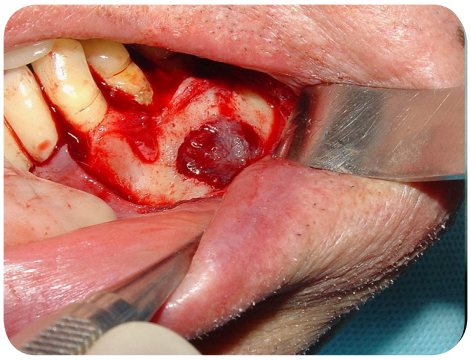

Exposição da lesão

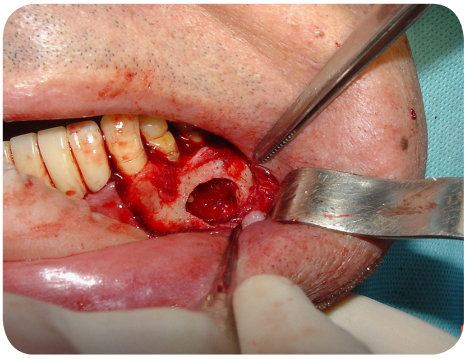

Exerese da lesão

Beta trifosfato de calcio

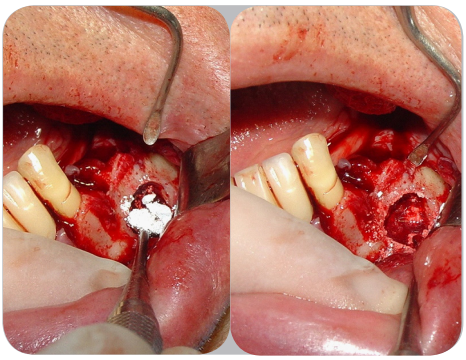

Acondicionamento do material na loja

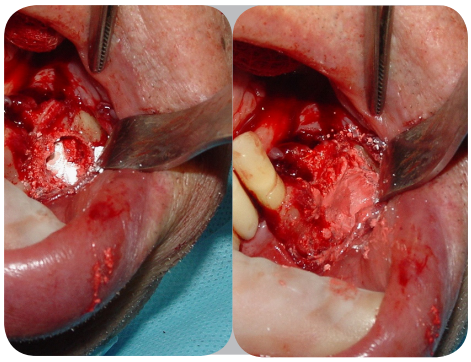

Com a absorção de sangue adquire consistência pastosa

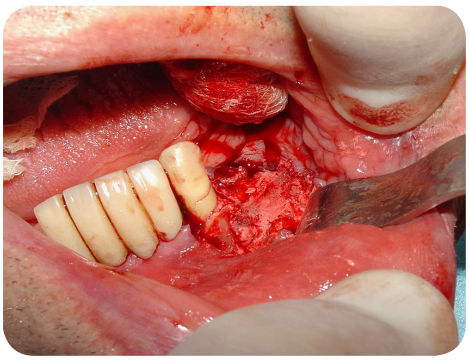

Aspecto final do enxerto

Caso Clínico

Cisto residual apical | Mandibula / Enxerto beta trifosfato de calcio

Depto. Clínico Bionnovation – Dr. Carlos A. A. Oliveira

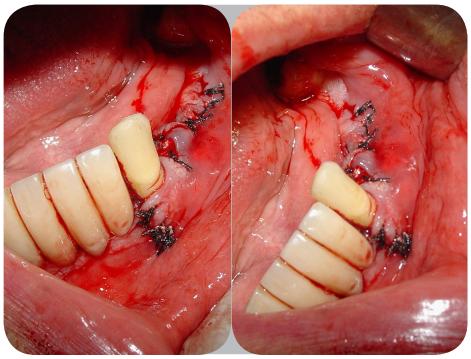

Retalho posicionado e sutura

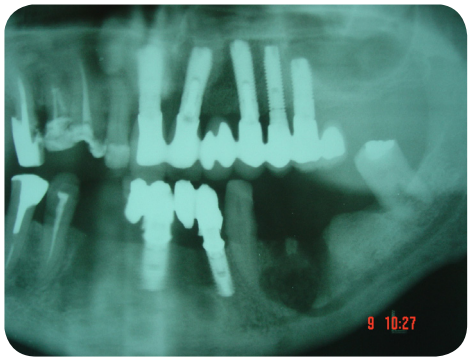

30 dias de pós operatório

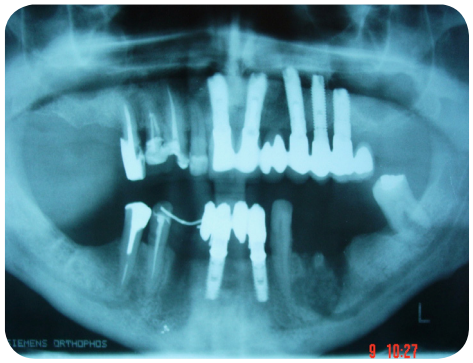

60 dias pó – presença de granulos

Professor Dr. Carlos A. A. Oliveira
Cirurgião Buco Maxilo Facial, Mestre em Patologia Bucal,
Especialista em Implantodontia, MBA em Gestão Empresarial. Atua como
Implantodontista há mais de 20 anos, ministra anualmente dezenas de cursos e palestras.
Diretor Clínico da Bionnovation Biomedical.